

Ultrasonography Imaging versus Waveform Capnography in Detecting Endotracheal Tube Placement during Intubation at a Tertiary Hospital

Shirish Shakti Maskay^{1,2*}, Ninadini Shrestha², Priska Bastola³, Bishwas Pradhan³, Anil Shrestha²

¹Department of Anesthesiology, Indira Gandhi Memorial Hospital, Male, Maldives, ²Department of Anesthesiology, Tribhuvan University Teaching Hospital, Institute of Medicine, Tribhuvan University, Kathmandu, Nepal, ³Department of Cardiothoracic and Vascular Anesthesiology, Manmohan Cardiothoracic Transplant and Vascular Centre, Institute of Medicine, Tribhuvan University, Kathmandu, Nepal

Abstract

Background: There is continued research to find new faster, highly accurate, easily accessible, and portable methods of confirming endotracheal tube position during intubation. A newer modality for visualizing endotracheal tube location is transtracheal or transcricothyroid ultrasonography. The aim of this study was to see if ultrasound machine can also be routinely used for the confirmation of endotracheal tube position in operating theaters along with capnograph. **Methods:** The study was observational and prospective, conducted from January 2017 to July 2017. Study locations were at the Tribhuvan University Teaching Hospital and Manmohan Cardiothoracic Vascular and Transplant Center operating rooms. Sample size taken was 95. **Results:** In the study, 11 patients had esophageal intubation out of the 95. The accuracy of both ultrasonography and capnography was found to be 96.84%. For ultrasonography, the sensitivity, specificity, along with positive predictive value and negative predictive value were 97.62%, 90.91%, 98.80%, and 83.33%, respectively, while that for capnography were found to be 96.43%, 100%, 100%, and 78.57%, respectively. The kappa value was calculated to be 0.749, which suggested the degree of agreement of result between the methods to be good. Compared to capnography, ultrasonography was found to be significantly faster for the confirmation of endotracheal tube location by 16.36 s (15.70–17.02) ($P = 0.011$). **Conclusion:** Both waveform capnography and ultrasonography were found to be accurate and reliable in confirming endotracheal tube location. The use of ultrasound during intubation can help confirm endotracheal tube location faster and also aid in precision when used along with capnography. Manual bag ventilations are not necessary when confirming endotracheal tube position by ultrasonography and thus may help in preventing aspiration of gastric contents into the lungs of the patient.

Keywords: Capnography, intubation, transtracheal ultrasonography, verification

INTRODUCTION

Endotracheal intubation establishes a definitive conduit for pulmonary ventilation and provides safety against aspiration.^[1] Confirming the endotracheal tube position correctly and timely is utmost important. The ideal method for this confirmation must be safe, reliable, easy, and fast.

Many regard the direct visualization of endotracheal tube entering the vocal cords and sustained exhaled carbon dioxide reading in capnograph as gold standard methods to assess correct endotracheal tube placement.^[2] The ease of use and reliability of capnography to establish correct endotracheal tube placement has been proven in many studies like those from Knapp *et al.*^[3]

and Grmec.^[4] However, capnography has limitations and might be unavailable in resource-limited centers. Bag ventilations need to be performed to see exhaled carbon dioxide waveforms. In the advent of esophageal intubation, this can result in the aspiration of stomach contents. The time taken to read three or six waveforms might be undesirable during emergency situations. The waveform readings might be confounding during some instances such as severe bronchospasm or shock states. A meta-analysis done by Li^[5] has shown good sensitivity and

Address for correspondence: Dr. Shirish Shakti Maskay, Department of Anesthesiology, Tribhuvan University Teaching Hospital, Institute of Medicine, Tribhuvan University, Kathmandu, Nepal. E-mail: shirishmaskay@gmail.com

Received: 26-09-2022 Revised: 01-02-2023 Accepted: 08-03-2023 Available Online: 10-11-2023

Access this article online

Quick Response Code:



Website:
<https://journals.lww.com/jmut>

DOI:
10.4103/jmu.jmu_98_22

This is an open access journal, and articles are distributed under the terms of the Creative Commons Attribution-NonCommercial-ShareAlike 4.0 License, which allows others to remix, tweak, and build upon the work non-commercially, as long as appropriate credit is given and the new creations are licensed under the identical terms.

For reprints contact: WKHLRPMedknow_reprints@wolterskluwer.com

How to cite this article: Maskay SS, Shrestha N, Bastola P, Pradhan B, Shrestha A. Ultrasonography imaging versus waveform capnography in detecting endotracheal tube placement during intubation at a tertiary hospital. J Med Ultrasound 2024;32:70-5.

specificity for endotracheal tube confirmation of end-tidal CO₂ measurement, but the meta-analysis has also suggested that the misidentification of esophageal endotracheal tube placement may occur with capnography in an emergency scenario (up to 7% false positives and false-negative rate of 3%). Li recommended to apply multiple methods to confirm tube position in emergency setting.

The use of ultrasound machine for various modalities is gaining popularity in operating rooms as well. Ultrasonography has been found to be highly specific and sensitive for endotracheal tube confirmation as demonstrated by the likes of Chou *et al.*^[6] and Das *et al.*^[7] When compared to capnography, Chou *et al.*^[8] found high diagnostic results from ultrasonography. Karacabey *et al.*^[9] found ultrasonography to be highly accurate and significantly faster than capnography. In their study, Pfeiffer *et al.*^[10] found ultrasound to be as quick as auscultation alone and quicker than combining auscultation and capnography in verifying endotracheal tube location.^[10] However, the high cost of ultrasound machines and a learning curve for beginners are potential challenges for its use.

During the recent COVID-19 pandemic, aerosol generation and spread prevention were highly discussed. Limiting manual bag ventilations can help prevent aerosol spread. Ultrasonography can be highly useful in this regard. Endotracheal tube can be confirmed before manual bag ventilation with ultrasonography. Furthermore, when auscultation is not feasible due to personal protective wear, ultrasonography can help rule out one-lung ventilation by observing lung sliding in both lungs.

METHODS

This was an observational study conducted prospectively on patients above 16 years of age admitted for elective surgery at the Tribhuvan University Teaching Hospital (TUTH) and Manmohan Cardiothoracic Vascular and Transplant Center (MCVTC). The study was conducted from the months of January to July in 2017. Ethical clearance from the institutional review board in the Institute of Medicine, Tribhuvan University (approval number: 250(6-11-E)²/073/074) and written consent from patients were taken. Patients with anticipated difficult airway, visible neck masses or abnormal anatomy of neck, poor grade of cardiopulmonary functional status (American Society of Anesthesiologists [ASA] physical status III and above), and those undergoing emergency surgeries were excluded from the study.

The formula used for sample size with $(1-\alpha)\%$ confidence level and maximum margin error of estimate of “ d ” for constructing confidence interval of true value of sensitivity or specificity using normal approximation was as follows^[11]:

$$n = \frac{Z_{\alpha/2}^2 \hat{P}(1-\hat{P})}{d^2}$$

Where \hat{P} is predetermined value of sensitivity or specificity that is ascertained by previous published data or clinician

experience or judgment.^[11] For $\alpha = 0.05$, $Z_{\alpha/2}$ is inserted by 1.96.^[11,12]

Excerpted from the meta-analysis done by Chou *et al.*^[6] where they found the sensitivity and specificity of suprasternal transtracheal ultrasound for endotracheal tube confirmation to be 0.98 and 0.94, respectively, the specificity value for \hat{P} in the equation was taken. Hence, setting margin of error “ d ” at 5%, we calculated as follows:

$$n = 1.96^2 \times 0.94 \times 0.06/0.05^2 = 86.66$$

Adjusting for 10% dropouts and defaulters, a sample size of 95 was thus taken.

Written consent was obtained and 103 patients were enrolled in the study. Eight patients however were excluded from the final study. There was unanticipated difficult intubation in one patient, and six patients had hypotension after the induction of anesthesia. There was also one instance of ultrasound machine error.

The study used high frequency (9–13 MHz) linear probe on Sonosite M Turbo (Fujifilm Sonosite Inc. USA, Mfg; 2013) ultrasound machine placed in transverse orientation, 5–10 mm above the suprasternal notch [Figure 1]. For capnography, both mainstream (Nihon Kohden BSM-2301K by Nihon Kohden Inc, Tokyo, Japan, 2008) and sidestream (Dräger Scio Four Gas Measurement Module by Dräger Medical GmbH, Lubeck, Germany, 2012) capnographs were used. Intubation was performed by anesthesia residents. Ultrasound was operated by trained and experienced anesthesia consultants. The capnograph reading was done by an anesthesia assistant. Positive or negative capnography finding would be announced by the anesthesia assistant after six ventilations based on the presence or absence of regular waveforms. Both methods for confirmation were studied simultaneously on the patient. The anesthesia consultant performing ultrasound would speak aloud mentioning the tube position when definitively assessed. The time taken for confirmation by both methods was started from the beginning of laryngoscopy during intubation and was noted by the researcher using a stopwatch.

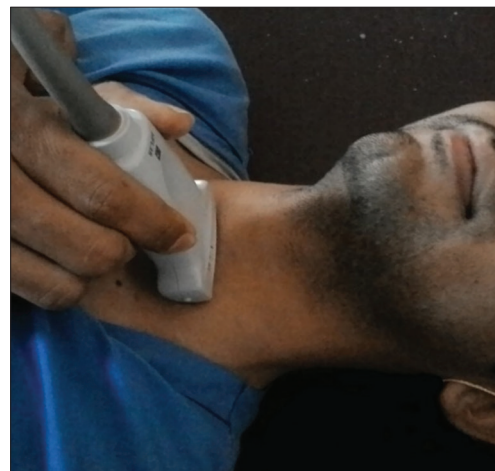

Figure 1: Figure showing linear probe placed above the suprasternal notch

After initial confirmation of the endotracheal tube position, reconfirmation was done through auscultation by another consultant anesthesiologist along with the observation of bilateral lung sliding in ultrasound in this study. Although not the accepted gold standard, bilateral lung sliding has also been shown to be reliable to confirm endotracheal intubation.^[10] Also keeping in mind about postintubation severe bronchospasm when there might absent lung sliding and no audible breath sounds, repeat laryngoscopy and visualization of the tube would be done by the consultant anesthesiologist for definite reconfirmation of the tube location specifically during esophageal intubation.

Normally, the trachea is seen as a hyperechoic curvilinear structure in transtracheal ultrasound with an acoustic shadow beyond it and comet tail artifact inside the shadow. The esophagus is more distal in the image, seen usually posterolateral to the trachea. It appears as an oval structure with hypoechoic center surrounded by hyperechoic wall layers [Figure 2].^[13,14]

When the tube is placed inside the trachea, a new artifact or increase in artifact appears in the region of the tracheal shadow. Shaking of the tube will further show motion artifacts and fluttering inside the region of trachea. With color Doppler, the color ray will be visible inside acoustic shadowing of the trachea during the shaking of the tube [Figure 3].^[14]

In esophageal intubation, the ultrasound image will present a separate hyperechoic structure with an acoustic shadow within the esophageal lumen. A new comet tail artifact, separate from and posterolateral to the comet tail artifact of the trachea can be seen. While shaking the tube, the color ray Doppler will appear outside the trachea [Figure 4].^[14]

RESULTS

Among the 95 patients, 51 were females and 44 males. The median age was 47 years (16–85 years range) and the median body mass index of the patients was 23.72 kg/m² (16.33–33.88 range). There were 46 ASA I patients and 49 ASA II patients in this study [Table 1].

Varying physical profile of the patients with differences in neck anatomy can affect laryngoscopy and performance of the neck ultrasound. However, patients with anticipated difficult airway including short or thick neck, large thyroid glands, and also known stiff laryngeal cartilages were excluded from the study. Thus, the demographic and physical attributes of the patients [Table 1] likely did not affect this study.

There were 11 actual esophageal intubations in this study (incidence 11.57%). The higher rate of esophageal intubation than usual reported (4%–10%, Li^[5]) was due to the participation of anesthesia residents including first year residents in this study to perform intubation. Ultrasonography falsely detected two tracheal intubations as esophageal and one esophageal intubation as tracheal. There were three false-negative (false esophageal location) and

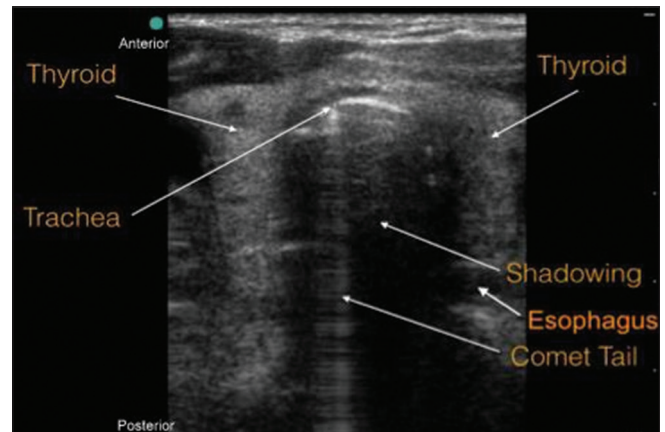


Figure 2: Ultrasound image showing trachea and esophagus above suprasternal notch.^[14] White arrows = for labelling purpose of the structures seen in the image

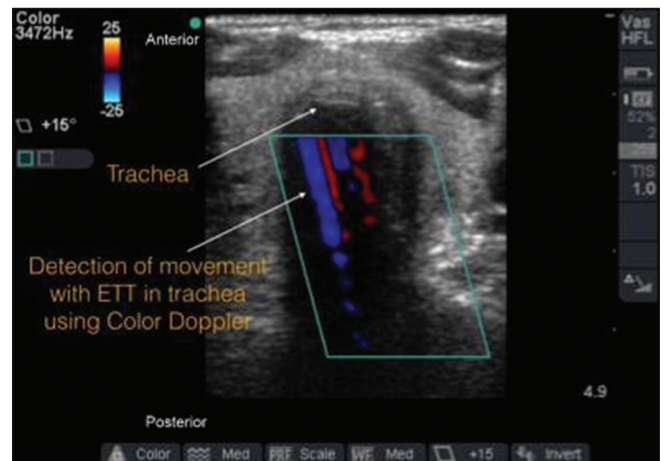


Figure 3: Figure showing color ray inside tracheal shadow while shaking the tube.^[14] White arrows = for labelling purpose of the structures seen in the image. Square box = area in the image where color doppler was applied

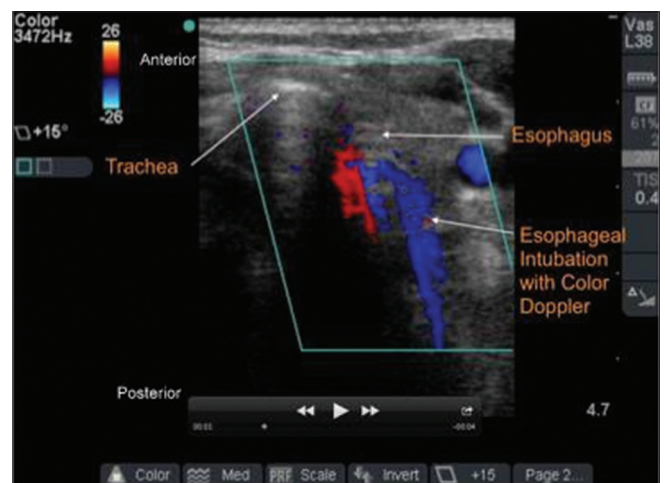


Figure 4: Ultrasound image with color Doppler during esophageal intubation.^[14] White arrows = for labelling purpose of the structures seen in the image. Square box = area in the image where color doppler was applied

no false-positive (false tracheal location) results given by waveform capnography [Figure 5].

Data analysis was done using Microsoft Excel 2010 spreadsheet (Microsoft Corporation, Washington, USA, 2010) and SPSS 23.0 (IBM SPSS Statistics for Windows, Version 23.0. by IBM Corp. Armonk, New York, 2015).

The sensitivity, specificity, predictive values, likelihood ratios and accuracy of both methods were calculated and compared [Table 2]. For confirmation of endotracheal tube position, both ultrasonography and waveform capnography were observed to be fairly accurate and reliable diagnostic methods [Table 2].

Cohen's kappa statistics was applied to analyze the degree of agreement between the results of the two methods. Kappa value of 0.749 (0.567–0.931) with standard error of 0.093 was found. A good degree of agreement between the results of the two methods was thus deduced.^[15]

The time for confirmation by ultrasonography was 26.79 ± 7.64 seconds (mean \pm standard deviation). Likewise, the time for confirmation by capnography was 43.03 ± 8.71 s. In this study, the median difference in time was 16 ± 3.23 s in favor

of ultrasonography. The difference in time was found to be highly significant ($P = 0.011$).

DISCUSSION

The sensitivity and specificity of ultrasonography in this study was found to be good and is comparable to that reported by Das *et al.*^[7] and Chou *et al.*^[6] The high accuracy of ultrasonography in confirming endotracheal location in this study is also similar to that found by previous researchers.^[8,16-18]

Suprasternal transtracheal ultrasound scanning with the probe in transverse orientation was done at real time in this study. Beside this, there are other ways of adopting ultrasound scanning for endotracheal tube confirmation. Scanning at the level of vocal cords, the fluttering of vocalis ligament can be observed in ultrasound image as the tube passes through. Singh *et al.*^[19] studied this method but found the accuracy to be only 71% with this scanning technique.

Ultrasound scanning can be done at the level of cricothyroid membrane and also just above the suprasternal area like in this study for confirming endotracheal tube location. The scan can be done in real time as the tube is passed through

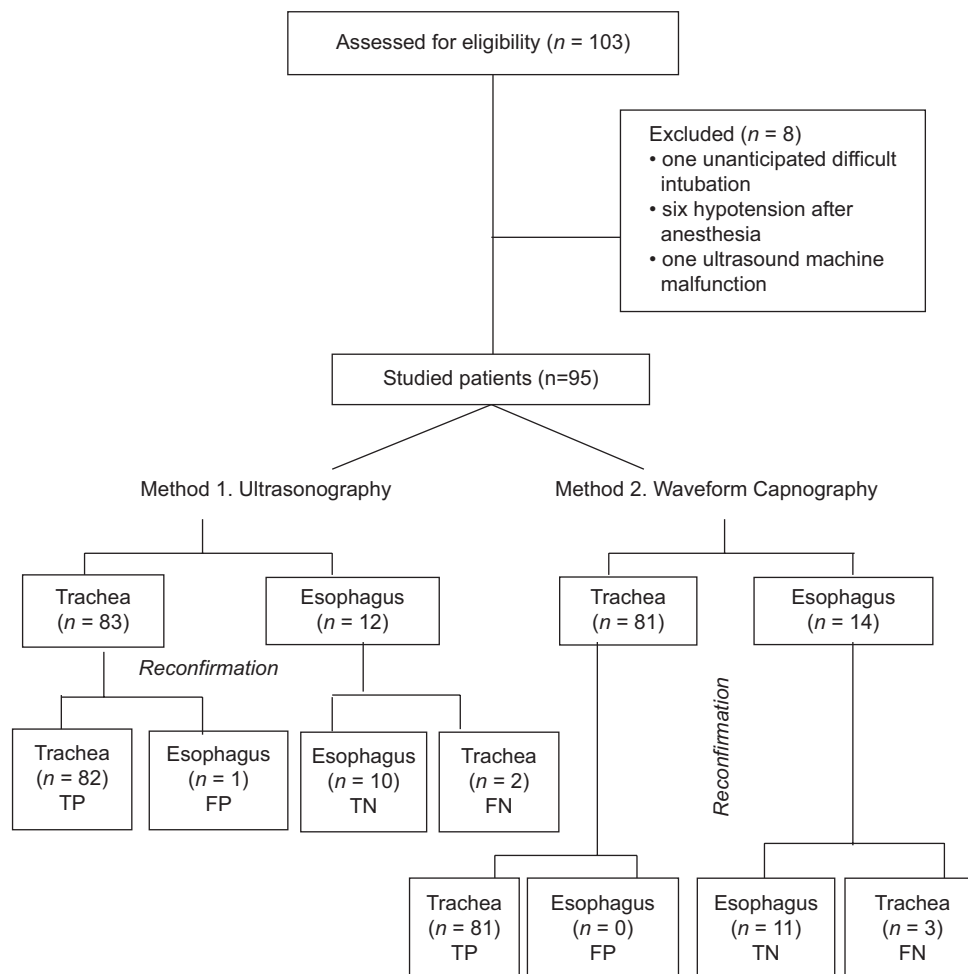


Figure 5: Flow diagram representing the study. TP: True positive, FP: False positive, TN: True negative, FN: False negative

Table 1: Distribution of patients according to demographic and clinical characteristics

| Characteristic | Number of patients |
|----------------------------------|--------------------|
| Age distribution | |
| 16–20 | 11 |
| 21–30 | 12 |
| 31–40 | 18 |
| 41–50 | 21 |
| 51–60 | 18 |
| >60 | 15 |
| BMI | |
| 16–18.5 (underweight) | 6 |
| 18.5–25 | 56 |
| 25–30 | 31 |
| 30–35 (moderately obese) | 2 |
| Ethnicity | |
| Brahmins | 38 |
| Chhetris | 21 |
| Newars | 14 |
| Magars | 7 |
| Others | 15 |
| Comorbidities in ASA II patients | |
| Valvular heart disease | 8 |
| Coronary heart disease | 15 |
| Vascular disease | 6 |
| HTN | 20 |
| Diabetes | 5 |
| CNS disorder | 8 |
| Hypothyroid | 6 |

HTN: Hypertension, ASA: American Society of Anesthesiologists, CNS: Central nervous system, BMI: Body mass index

Table 2: Diagnostic characteristics of ultrasonography and waveform capnography

| | 95% CI | |
|---------------------------|-------------------|----------------------|
| | Ultrasonography | Waveform capnography |
| Specificity | 90.91 (58.7–99.7) | 100 (71.5–100) |
| Sensitivity | 97.62 (91.6–99.7) | 96.43 (89.9–99.2) |
| Accuracy | 96.84 (92.9–100) | 96.84 (92.9–100) |
| PPV | 98.80 (92.6–99.8) | 100 (100–100) |
| NPV | 83.33 (55.6–95.2) | 78.57 (54.6–91.7) |
| Positive likelihood ratio | 10.74 | ∞ |
| Negative likelihood ratio | 0.03 | 0.04 |

CI: Confidence interval, PPV: Positive predictive value, NPV: Negative predictive value

or in static manner after intubation. Static ultrasonography was demonstrated to be accurate and reliable in studies by Adi *et al.*^[18] and Chou *et al.*^[8] Many have opined that the ultrasound probe position could interfere with the act of laryngoscopy during real-time use.^[8,18] However, real-time scanning, when used, has been found to be effective and rarely mentioned to interfere in performing laryngoscopy. In fact, Chou *et al.*^[6] in their meta-analysis demonstrated real-time tracheal ultrasonography to have slightly better sensitivity of 0.94 (0.86–0.98) compared to static (postintubation) technique

which had sensitivity of 0.91 (0.70–0.98). Likewise, Milling *et al.*^[20] found the specificity and sensitivity of transcricothyroid ultrasonography in real time to be 100% and 97%, respectively, for endotracheal tube location confirmation. Lung sliding in ultrasound scan can also be used for confirmation. Pfeiffer *et al.*^[10] and Weaver *et al.*^[21] have found lung sliding to be accurate in detecting endotracheal tube position.

Ultrasound scanning done real time at suprasternal level in transverse probe orientation was significantly faster than observing waveforms in capnograph to confirm endotracheal tube location in this study. Karacabey *et al.*^[9] performed transtracheal ultrasound scanning at same level but after intubation and still found ultrasonography to be faster by a mean of 5.9 s than observing regular capnograph waveforms in their study. Using lung sliding in the chest, Pfeiffer *et al.*^[10] found that lung ultrasound was in average 7.1 s faster to confirm endotracheal tube position than capnography.

There were some limitations in this study as well. Two types of capnographs, i.e., sidestream and mainstream devices were used. Sidestream capnographs have a sampling delay time (2–4 s in our study) to read the exhaled CO₂ values compared to mainstream capnographs. There were different ultrasound operators (anesthesia consultants trained in airway ultrasound) in this study. These factors could affect the time taken to confirm endotracheal tube location by the respective methods. Auscultation and lung sliding in ultrasound were used for reconfirmation of tube position due to feasibility (contrast to X-ray or other imaging modalities), which could be inferior compared to capnography or transtracheal ultrasonography.

CONCLUSION

Waveform capnography and ultrasonography are both accurate and reliable methods to confirm endotracheal tube location. Confirmation of endotracheal tube position by real-time ultrasound scanning can be faster than observing capnograph waveforms. Manual bag ventilations can be avoided while confirming endotracheal tube position by ultrasound scan and this may help to prevent instances of aspiration of stomach contents into the patient's lungs.

Acknowledgments

We would like to acknowledge the contributions of everybody in helping to conduct the study at MCVTC and TUTH, including all the anesthesia assistants, nursing staffs, OT attendants, senior and junior residents, and medical officers from MCTVC and TUTH OT. We extend warm and sincere thanks to all the anesthesia faculties involved in the study: Dr. Renu Gurung, Dr. Subhash Acharya, Dr. Hira Khadka, Dr. Gentle Shrestha, Dr. Binita Acharya, Dr. Pramesh Shrestha, Dr. Diptesh Aryal, Dr. Bigen Man Shakya, Dr. Amit Sharma Bhattarai, Dr. Megha Koirala, Dr. Navindra Raj Bista, Dr. Bashu Dev Parajuli, Dr. Pankaj Joshi, Dr. Pradip Tiwari, Dr. Madindra Basnet, Dr. Bibhush Shrestha, Dr. Shailendra Sigdel, Dr. Arjun Gurung, and Dr. Bidur Dhungel. We would like to thank anesthesia residents Dr. Bipin Karki, Dr. Kriti

Devkota, Dr. Raj Kumar Yadav, Dr. Santosh Acharya, Dr. Sachit Sharma, Dr. Prajjwol Deo Bhatta, Dr. Rishabh Ravi, Dr. Pujan Balla, Dr. Anshu Kumari, Dr. Lokendra Mandal, Dr. Deepika Subedi, Dr. Abdulla Ilyas, and Dr. Saroj Aryal for their collaboration. Special thanks to Dr. Arjun Limbu for his help in statistical analysis.

Financial support and sponsorship

Nil.

Conflicts of interest

There are no conflicts of interest.

REFERENCES

- Hagberg CA, Artime CA. Airway management in the adult. In: Miller RD, Cohen NH, Eriksson LI, Fleisher LA, Wiener-Kronish JP, Young WL, editors. *Miller's Anesthesia*. 8th ed. Philadelphia: Elsevier Saunders; 2015. p. 1655.
- Rudraraju P, Eisen LA. Confirmation of endotracheal tube position: A narrative review. *J Intensive Care Med* 2009;24:283-92.
- Knapp S, Kofler J, Stoiser B, Thalhammer F, Burgmann H, Posch M, *et al.* The assessment of four different methods to verify tracheal tube placement in the critical care setting. *Anesth Analg* 1999;88:766-70.
- Grmec S. Comparison of three different methods to confirm tracheal tube placement in emergency intubation. *Intensive Care Med* 2002;28:701-4.
- Li J. Capnography alone is imperfect for endotracheal tube placement confirmation during emergency intubation. *J Emerg Med* 2001;20:223-9.
- Chou EH, Dickman E, Tsou PY, Tessaro M, Tsai YM, Ma MH, *et al.* Ultrasonography for confirmation of endotracheal tube placement: A systematic review and meta-analysis. *Resuscitation* 2015;90:97-103.
- Das SK, Choupoo NS, Haldar R, Lahkar A. Transtracheal ultrasound for verification of endotracheal tube placement: A systematic review and meta-analysis. *Can J Anaesth* 2015;62:413-23.
- Chou HC, Tseng WP, Wang CH, Ma MH, Wang HP, Huang PC, *et al.* Tracheal rapid ultrasound exam (T.R.U.E.) for confirming endotracheal tube placement during emergency intubation. *Resuscitation* 2011;82:1279-84.
- Karacabey S, Sanrı E, Gencer EG, Güneysel O. Tracheal ultrasonography and ultrasonographic lung sliding for confirming endotracheal tube placement: Speed and Reliability. *Am J Emerg Med* 2016;34:953-6.
- Pfeiffer P, Rudolph SS, Børglum J, Isbye DL. Temporal comparison of ultrasound versus auscultation and capnography in verification of endotracheal tube placement. *Acta Anaesthesiol Scand* 2011;55:1190-5.
- Kasiulevičius V, Šapoka V, Filipavičiūtė R. Sample size calculation in epidemiological studies. *Gerontologija* 2006;7:225-31.
- Hajian-Tilaki K. Sample size estimation in diagnostic test studies of biomedical informatics. *J Biomed Inform* 2014;48:193-204.
- Stone M, Chan W. Focused Ultrasound for Airway Management. Philips Tutorial. Phillips HealthCare; 2014. Available from: <https://www.philips.com/CCEMeducation>. [Last accessed on 2016 Dec 28].
- Chao A, Gharabaghian L. Tips and Tricks: Airway Ultrasound. Texas USA: ACEP; 2016. Available from: <https://www.acep.org/Content.aspx?id=102309>. [Last accessed on 2017 Jan 17].
- Altman DG. Statistics in medical journals: Developments in the 1980s. *Stat Med* 1991;10:1897-913.
- Nasreen M, Amin M, Humayun A, Ali W, Rana HA, Farooq M. Diagnostic accuracy of tracheal rapid ultrasound exam (TRUE) for confirming endotracheal tube placement in emergency intubation using X-ray as gold standard. *PJMHS* 2017;11:602-4.
- Gottlieb M, Bailitz JM, Christian E, Russell FM, Ehrman RR, Khishfe B, *et al.* Accuracy of a novel ultrasound technique for confirmation of endotracheal intubation by expert and novice emergency physicians. *West J Emerg Med* 2014;15:834-9.
- Adi O, Chuan TW, Rishya M. A feasibility study on bedside upper airway ultrasonography compared to waveform capnography for verifying endotracheal tube location after intubation. *Crit Ultrasound J* 2013;5:7.
- Singh M, Chin KJ, Chan VW, Wong DT, Prasad GA, Yu E. Use of sonography for airway assessment: An observational study. *J Ultrasound Med* 2010;29:79-85.
- Milling TJ, Jones M, Khan T, Tad-y D, Melniker LA, Bove J, *et al.* Transtracheal 2-d ultrasound for identification of esophageal intubation. *J Emerg Med* 2007;32:409-14.
- Weaver B, Lyon M, Blaivas M. Confirmation of endotracheal tube placement after intubation using the ultrasound sliding lung sign. *Acad Emerg Med* 2006;13:239-44.